



---

## Uploaded to VFC Website

▶▶▶ February 2013 ◀◀◀

---

This Document has been provided to you courtesy of Veterans-For-Change!

Feel free to pass to any veteran who might be able to use this information!

For thousands more files like this and hundreds of links to useful information, and hundreds of "Frequently Asked Questions, please go to:

[Veterans-For-Change](http://Veterans-For-Change.com)

---

*Veterans-For-Change is a 501(c)(3) Non-Profit Corporation  
Tax ID #27-3820181*

***If Veteran's don't help Veteran's, who will?***

We appreciate all donations to continue to provide information and services to Veterans and their families.

[https://www.paypal.com/cgi-bin/webscr?cmd=\\_s-xclick&hosted\\_button\\_id=WGT2M5UTB9A78](https://www.paypal.com/cgi-bin/webscr?cmd=_s-xclick&hosted_button_id=WGT2M5UTB9A78)

---

**Note:**

VFC is not liable for source information in this document, it is merely provided as a courtesy to our members.



# Mixed Connective Tissue Disease

STEPHEN D. PRYSTOWSKY, MD, *San Francisco*

*A study was done that involved 46 patients with high-titer serum antibody to ribonucleoprotein (RNP). Common cutaneous manifestations included swollen hands or sclerodactyly (50 percent), cutaneous lupus erythematosus (48 percent), periungual telangiectasia (46 percent), alopecia (46 percent), dyspigmentation (28 percent), photosensitivity (28 percent) and vasculitis (22 percent). Frequent systemic characteristics included Raynaud phenomenon (93 percent), arthritis or arthralgia (91 percent), adenopathy (43 percent), vascular headaches (35 percent), serositis (35 percent), hoarseness (28 percent), myositis (26 percent), sicca syndrome (24 percent), renal disease (17 percent) and central nervous system disease (9 percent). Associated laboratory findings included antinuclear antibodies (100 percent), epidermal nuclear IgG deposition (91 percent), hypergammaglobulinemia (78 percent), esophageal dysmotility (61 percent), abnormal pulmonary function (59 percent), rheumatoid factor (57 percent), lupus erythematosus cells (37 percent), positive lupus band test (34 percent), hypocomplementemia (28 percent) and elevated anti-nDNA (21 percent).*

*It appears that patients with high-titer anti-RNP (without appreciable amounts of "anti-Sm") have a high prevalence of Raynaud phenomenon and a low prevalence of progressive renal insufficiency and severe central nervous system disease.*

IN 1972, Sharp and co-workers<sup>1</sup> described a group of patients designated as having mixed connective tissue disease (MCTD) with benign features often compatible with systemic lupus erythematosus (SLE), but suggestive of scleroderma or polymyositis, or both. Serum antibody to a ribonuclease-sensitive extractable nuclear antigen (ENA) termed anti-RNP is, by definition, the immunologic marker of this connective tissue

disease subset. This paper expands the ribonucleoprotein (RNP) spectrum of connective tissue disease to a patient population more representative of private practice than of referral centers.

## Patients and Methods

The only criterion for patient selection was the presence of serum antibody in high titer (mean = 1:149,200) to ribonucleoprotein. Forty-six patients were examined by the author on one or more occasions and comprehensive studies carried out using a pretested clinical research protocol. Of the patients, 39 were women and

From the Department of Dermatology, University of California, San Francisco, School of Medicine.

Submitted, revised, November 8, 1979.

Reprint requests to: Stephen D. Prystowsky, MD, 325 Marks Rd., Danville, CA 94526.

## MIXED CONNECTIVE TISSUE DISEASE

### ABBREVIATIONS USED IN TEXT

ANA=antinuclear antibody  
 ENA=extractable nuclear antigen  
 LE=lupus erythematosus  
 MCTD=mixed connective tissue disease  
 RNase=ribonuclease  
 RNP=ribonucleoprotein

7 were men (sex ratio, 5.6:1). Thirty-two patients were white, seven were black and seven were Oriental. The black and Oriental patients were all women. Ages ranged from 9 to 53 years, with a mean age of 36. The presence or absence of the cutaneous manifestations listed later in this paper in Table 3 were specifically noted for each patient. The presence of the systemic characteristics in Table 4 were prospectively recorded. The presenting symptom was also recorded for each patient and the laboratory values listed in Table 5 were determined for most of them.

Antibody to extractable nuclear antigen was determined by the hemagglutination method of Sharp and co-workers.<sup>1</sup> This test was carried out using ENA-coated sheep erythrocytes before and after ribonuclease (RNase) treatment. A fall in titer of four or more dilutions after treatment was interpreted as ribonuclease-sensitive and indicative of antibody to ribonucleoprotein.

Cutaneous immunoglobulin deposits were detected by direct immunofluorescence of biopsy specimens of both normal skin exposed to the sun (wrist and forearm) and nonexposed skin (medial forearm near the antecubital fossa, back or buttock) as previously described.<sup>2</sup>

The antinuclear antibody (ANA) test was carried out by the method of Holborow and colleagues<sup>3</sup>; total hemolytic complement ( $CH_{50}$ ) by the method of Kabat and Mayer<sup>4</sup>; the third and fourth components of complement (C3 and C4) were measured by radial immunodiffusion; the  $C1_q$  component of complement was determined by the method of Agnello and associates.<sup>5</sup> Antibody to double-stranded (native) DNA was determined by the millipore filter assay of Ginsberg and Keiser.<sup>6</sup> Ninety-five percent confidence intervals are recorded for each clinical or laboratory observation.

### Results

Figure 1 shows anti-ENA titers before and after RNase digestion. Of the 46 patients designated as RNase sensitive, 45 had a fall in titer of a least four tube dilutions; 34 of these patients' titration values dropped to less than 1:200 after antigen digestion with RNase. Only three patients had appreciable titers of an RNase-resistant ENA (termed "anti-Sm"). Thirty-eight patients had anti-RNP

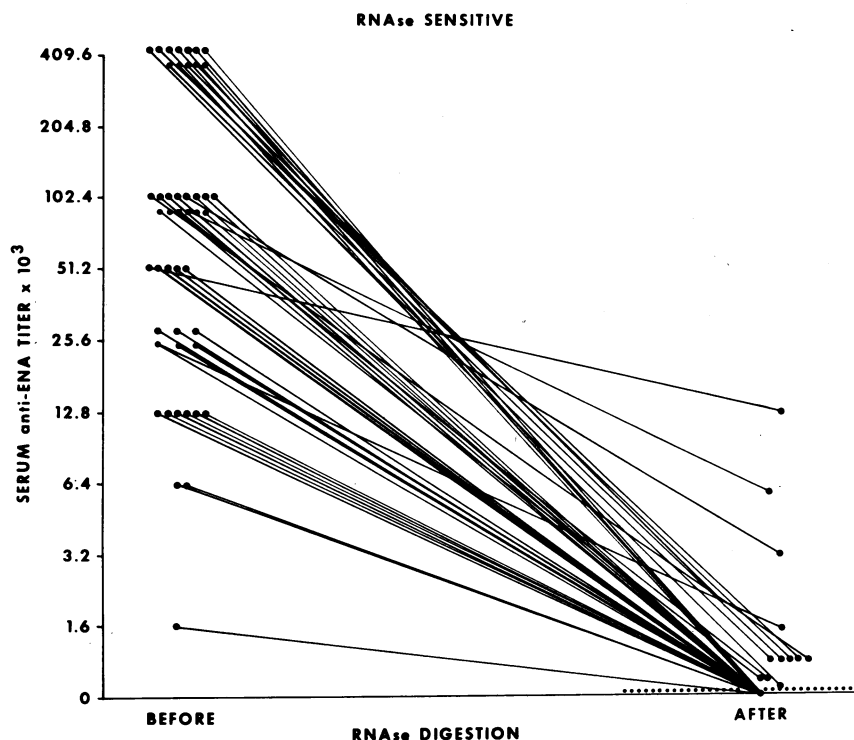


Figure 1.—Serum anti-ENA titers in 46 patients before and after ribonuclease digestion.

# MIXED CONNECTIVE TISSUE DISEASE

TABLE 1.—Presenting Features in Patients With Mixed Connective Tissue Disease\*

Presenting Feature	Patients (%)
Arthritis/arthralgia	21 (46)
Raynaud phenomenon	13 (28)
Cutaneous lupus erythematosus (LE)	7 (15)
chronic (discoid)	4 (9)
subacute	2 (4)
lupus profundus	1 (2)
Serositis	1 (2)
Nephrotic syndrome	1 (2)
Idiopathic thrombocytopenic purpura	1 (2)
Sclerodactyly	1 (2)
Alopecia	1 (2)

\*All cases included presence of high-titer serum antibody to ribonucleoprotein.

TABLE 2.—Development of Additional Signs or Symptoms in 46 Patients With Mixed Connective Tissue Disease

	Years to Development of Next Manifestation			
	<1 Yr	1-1.9 Yrs	2-3.9 Yrs	>4 Yrs
Patients with arthritis	12	4	2	3
Patients with Raynaud phenomenon	6	1	2	4*
Patients with cutaneous lupus erythematosus	1	3	1	2

\*Longest period to onset was 16 years.

TABLE 3.—Cutaneous Manifestations in 46 Patients With High-Titer Antibody to Ribonucleoprotein

Cutaneous Manifestation	Patients	
	No. Positive (%)	Percentage with 95% Confidence Intervals
Swollen hands or sclerodactyly	23 (50)	35-65
Cutaneous lupus erythematosus (LE)	22 (48)	33-63
chronic (discoid)	8 (13)	8-31
subacute	13 (28)	16-43
acute (malar)	4 (9)	2-21
lupus profundus	1 (2)	0-12
Periungual telangiectasia	21 (46)	31-61
Alopecia	21 (46)	31-61
Dyspigmentation	13 (28)	16-43
Photosensitivity	13 (28)	16-43
Vasculitis	10 (22)	11-36
Acrocyanosis	10 (22)	11-36
Mucous membrane ulceration	10 (22)	11-36
Pronounced facial telangiectasia	8 (17)	8-31
Erythema (elbows/knees/knuckles)	7 (15)	6-29
Cutaneous sclerosis	7 (15)	6-29
Livedo reticularis	7 (15)	6-29
Urticaria	5 (11)	4-24
Subcutaneous nodules	5 (11)	4-24
Heliotrope lids	3 (7)	1-18
Calcinosis cutis	2 (4)	1-15
Petechiae	2 (4)	1-15
Gottron papules	1 (2)	0-12

titers measuring 1:25,600 or greater. The mean titer was 1:149,200 and the median was 1:102,400. The highest antibody titer was recorded for patients with several determinations; sera were not diluted greater than 1:409,600.

The presenting clinical features are shown in Table 1. Additional clinical signs or symptoms developed in most of the patients within two years (Table 2). The Raynaud phenomenon usually developed early in the course of the disease when it was not the presenting feature. In 15 patients it occurred in less than a year; in four it developed in less than two years, and in five it occurred in less than four years. In six others it occurred more than four years after onset of MCTD (the longest period was 12 years). The three patients in whom the Raynaud phenomenon had not yet developed, had had MCTD for two, four and six years, respectively, at the time of the study.

Table 3 shows the cutaneous manifestations of the 46 patients. Swollen hands or sclerodactyly were observed in 23 patients (50 percent). Most of these patients had puffy fingers, without much cutaneous sclerosis; only two patients had tightly bound-down skin with contractures. The entire spectrum of cutaneous LE was observed: 8 patients had persistent destructive discoid lesions, 13 had diffuse, nonscarring, poorly demarcated subacute lesions and 4 patients had an acute malar eruption. Pigmentary disturbances were found in 13 patients (28 percent), and included focal and diffuse hyperpigmentation, poikiloderma, vitiligo and hypopigmentation with follicular retention of pigment (the "salt and pepper" depigmentation of scleroderma). Cutaneous vasculitis was present in ten patients (22 percent). This group included patients with biopsy-proved leukocytoclastic vasculitis manifested clinically by purpuric papules and ulcers on the legs as well as patients with transient, painful dermal nodules that often occurred on the hands. These nodules usually lasted two to six weeks and resolved without scarring. Biopsy specimens showed either a perivascular lymphocytic infiltrate or leukocytoclastic vasculitis. Other cutaneous findings are listed in the table.

Table 4 depicts the systemic clinical features of the 46 patients. Raynaud phenomenon occurred in 43 (93 percent) and was frequently the most persistent and bothersome symptom as well as the one least responsive to therapy. The arthritis was usually evanescent and nondeform-

# MIXED CONNECTIVE TISSUE DISEASE

ing as usually occurs in SLE. Only four patients had a deforming arthritis; two of these had mild to moderate erosive changes noted on x-ray films. Mild myalgia, fatigue and weakness were observed in 26 patients (57 percent); moderate to severe myositis with elevated muscle enzymes was less frequent (26 percent). Five patients had lymph node biopsies done to rule out a lymphoproliferative malignant condition. Episodes of pleurisy (14 patients) or pericarditis (seven patients) occurred in 35 percent. Prolonged hoarseness (unassociated with sicca syndrome) was observed in 28 percent. Renal disease was present in eight patients, manifested as persistent mild proteinuria (two), mesangial or focal glomerulitis (two), membranoproliferative glomerulonephritis (one) and membranous glomerulonephritis (three). At present, only one of these patients has renal insufficiency. Four patients had central nervous system disease, three had trigeminal sensory neuropathy and one had a bilateral neurosensory hearing loss. No patients had seizures, psychoses or strokes. Other features are listed in the table.

Table 5 summarizes the laboratory findings in these patients. In all patients results of ANA tests were positive, 83 percent with high titers. The immunofluorescent nuclear staining patterns were as follows: speckled, 39 (85 percent); speckled only, 28 (61 percent); homogeneous, 18 (39 percent), and peripheral, 9 (20 percent). The nucleolar staining pattern was not observed. Seventeen (37 percent) of the patients had two or more patterns.

Speckled (particulate) epidermal nuclear IgG deposition occurred in 91 percent on direct immunofluorescence of normal skin. This immunofluorescent marker for very high-titered ENA antibody has been described in detail elsewhere.<sup>7-10</sup> The 91 percent prevalence of epidermal nuclear IgG localization in MCTD is probably too high since many of these patients were selected for another study by this finding.<sup>9,10</sup>

Esophageal dysmotility occurred in 61 percent of the patients although dysphagia was present in only 15 percent. Abnormal pulmonary function tests were present in 59 percent of those tested. Some 38 percent had a mild restrictive defect, 34 percent had a mild diffusion defect and 13 percent had abnormal restrictive and diffusion tests. Generally, x-rays of the chest showed no abnormalities in these patients.

Subepidermal immunoglobulins in normal skin

(positive lupus band test) were observed in 15 of 44 (34 percent) patients. In 13 of 34 (38 percent) patients, tests were positive on sun-exposed skin; 6 of 28 (21 percent) were positive on skin not exposed to the sun. The frequency distribution of subepidermal immunoglobulin deposits in these 15 patients included IgG and IgM in five, IgG only in six and IgM only in

TABLE 4.—Systemic Characteristics of 46 Patients With High-Titer Antibody to Ribonucleoprotein

Systemic Characteristic	Patients	
	No. Positive (%)	Percentage With 95% Confidence Intervals
Raynaud phenomenon . . . . .	43 (93)	82-99
Arthritis or arthralgia . . . . .	42 (91)	79-98
Adenopathy . . . . .	20 (43)	29-59
Vascular headache . . . . .	16 (35)	21-50
Pleurisy/pericarditis . . . . .	16 (35)	21-50
Prolonged hoarseness . . . . .	13 (28)	16-43
Hepatomegaly/splenomegaly . . . . .	13 (28)	16-43
Myositis . . . . .	12 (26)	14-41
Sicca syndrome . . . . .	11 (24)	13-39
Renal disease . . . . .	8 (17)	8-31
Dysphagia . . . . .	7 (15)	6-29
Central nervous system disease . . . . .	4 (9)	2-21
Dyspnea . . . . .	4 (9)	2-21
Thrombophlebitis . . . . .	2 (4)	1-15
Thyroid disease . . . . .	2 (4)	1-15
Idiopathic thrombocytopenic purpura . . . . .	2 (4)	1-15

TABLE 5.—Laboratory Findings in 46 Patients With High-Titer Antibody to Ribonucleoprotein

Studies	Patients		
	No. Studied	No. Positive (%)	Percentage With 95% Confidence Intervals
"Anti-RNP" antibody . . . . .	46	46 (100)	
Antinuclear antibody . . . . .	46	46 (100)	92-100
Epidermal nuclear IgG deposition . . . . .	44	40 (91)	78-97
Hypergammaglobulinemia . . . . .	40	31 (78)	62-89
Erythrocyte sedimentation rate (>30 mm per hour) . . . . .	43	33 (77)	61-88
Esophageal dysmotility . . . . .	33	20 (61)	42-77
Abnormal pulmonary function . . . . .	32	19 (59)	41-76
Rheumatoid factor . . . . .	46	26 (57)	41-71
LE cells . . . . .	41	15 (37)	22-53
Lupus band test . . . . .	44	15 (34)	20-50
Hypocomplementemia . . . . .	43	12 (28)	15-44
Elevated anti-nDNA . . . . .	43	9 (21)	10-36
Leukopenia (leukocytes <4,000 per cu mm) . . . . .	44	9 (20)	10-35
Direct Coombs test . . . . .	27	5 (19)	6-38
Anemia (Hb <11 grams per dl) . . . . .	44	8 (18)	8-33
Cryoglobulinemia . . . . .	30	4 (13)	4-31
Biologic false-positive . . . . .	36	2 (6)	1-19
([+] VDRL; [-] FTA-ABS)			

four. In 16 patients biopsy specimens were taken simultaneously from both sites: both tests were positive in three patients and both tests were negative in ten patients; in three patients (19 percent) tests were positive on sun-exposed sites and negative on nonexposed skin.

Twelve patients (28 percent) had hypocomplementemia. In 11 of these there was only mild to moderate depression of serum complement. In one patient hemolytic complement was substantially depressed for a prolonged period. Her anti-nDNA was within normal limits, however, and she had no clinical evidence of renal disease. Some 21 percent of the patients had elevated serum antibodies to nDNA. Mild to moderate titers were present in seven patients; two patients had high titer antibodies to nDNA. Of the latter, one patient had no clinical evidence of renal disease and the other had membranous glomerulonephritis without renal insufficiency. Other laboratory abnormalities are noted in Table 5.

## Discussion

Frequently, there appears to be little value in discussing whether a patient suffers from a specific disease, and the diagnosis becomes almost a matter of opinion.<sup>11</sup> Sharp and co-workers<sup>1,12</sup> have contributed to medicine by carefully defining a characteristic subset of connective tissue disease (CTD). Many, if not most, of these patients may fulfill arbitrary criteria for other diagnoses of CTD. However, it appears that most patients seen at university hospitals with high-titer antibody to RNP (without appreciable amounts of "anti-Sm") have clinical or laboratory manifestations of two or more CTD.

The purpose of this report is to extend the RNP spectrum of CTD to include a patient population more representative of private practice. Approximately 75 percent of the patients in this report are managed by physicians in private practice or in the military. In general, these patients as a group, have a milder form of the RNP subset than previously reported.<sup>1,8,12-15</sup>

The diagnosis of RNP subset or MCTD should be suspected in patients with Raynaud phenomenon and nondeforming (nonerosive) arthritis or arthralgia. Such cases are sometimes misdiagnosed as rheumatoid arthritis because these patients frequently have high-titered rheumatoid factors (RF). It appears that moderate to severe erosive arthritis is uncommon in patients with anti-RNP even in the presence of prolonged elevations of

RF. The combination of subacute or chronic cutaneous lupus erythematosus, Raynaud phenomenon and arthralgia is frequently observed by dermatologists and appears to have a high association with anti-RNP. We recently observed the high prevalence of subacute and chronic cutaneous LE in this RNP subset.<sup>8</sup> We also reported two patients with discoid lupus erythematosus (DLE) in whom MCTD (RNP subset) developed.<sup>16</sup> Six additional such patients are reported here.

The association of frequent mild to moderate vascular headaches with anti-RNP has been noted recently. Most of these patients with cyclical, throbbing headaches experienced prodromal symptoms (eight had visual auras), and five suffered nausea or vomiting. None of the 16 patients with vascular headaches had prominent suboccipital pain or tension suggestive of the diagnosis of muscle contraction headaches. The high prevalence of vascular headaches may be related to the Raynaud phenomenon. A detailed neurologic investigation of vascular headaches in MCTD has been reported elsewhere.<sup>17</sup>

Frequent episodes of prolonged hoarseness, lasting for weeks, appear to be a new finding. However, none of the 13 patients in whom hoarseness occurred had sicca syndrome. Many of them had frequent ear, nose and throat examinations which gave normal findings. Myositis (myalgia and objective muscle weakness with increased muscle enzyme values) was much less common in this series than in previous reports.<sup>1,12-15</sup> Muscle weakness was frequently clinically more prevalent than the objective laboratory tests indicated (muscle enzymes, electromyogram and muscle biopsy).

Sicca syndrome (xerostomia or keratoconjunctivitis sicca) occurred in 11 patients. In eight of these patients there was either an abnormal finding on a Shirmer test or a lip biopsy gave positive findings, indicating focal lymphocytic infiltration into affected glandular tissue.<sup>18</sup>

The low prevalence of severe central nervous system disease and progressive renal insufficiency is perhaps the most important feature of the RNP subset and has been previously well described.<sup>1,8,12-14,19,20</sup> Of note is the high prevalence of abnormal pulmonary function test results (59 percent) and esophageal dysmotility (61 percent) associated with a low prevalence of dyspnea (9 percent) and dysphagia (15 percent).

The cutaneous manifestations of the 46 patients primarily show features of SLE and sclero-

derma. A low prevalence of typical skin changes suggestive of dermatomyositis was noted. The most striking skin lesions were cutaneous LE (48 percent) and swollen hands or sclerodactyly (50 percent). However, extensive cutaneous sclerosis that characterizes scleroderma was uncommon (15 percent). Alopecia, though common (46 percent), was usually mild. Often a beautician or spouse first noted the loss of hair. The clinical appearance of hair loss was that of a prolonged telogen effluvium. In most cases, the patient's hair appeared normal and only a careful history showed that significant hair loss had occurred. These cutaneous findings are similar to those we have previously reported.<sup>8</sup>

It is likely that all patients had high-titer speckled (particulate) antinuclear antibodies at some time during their course because anti-ENA is associated with a speckled pattern, and the pattern observed by direct immunofluorescence of normal skin was also speckled. The homogeneous pattern may have obscured the speckled pattern in certain patients when both were present in high titer.

Most of the patients had relatively mild disease and usually responded rapidly to low-dose corticosteroid therapy. Patients with arthralgia, myalgia and fatigue often responded well to non-steroid anti-inflammatory agents alone. However, Raynaud phenomenon was resistant to all forms of therapy.

Antibody to RNP appears to be another in a growing list of immunologic markers associated with certain distinct clinical manifestations. The early differentiation of this RNP subset—involving a less aggressive clinical course characterized by a high prevalence of the Raynaud phenomenon, a low prevalence of progressive renal insufficiency and severe CNS disease and a good response to low-dose corticosteroids—is important for prognostic purposes.

## REFERENCES

1. Sharp GC, Irvin WS, Tan EM, et al: Mixed connective tissue disease: An apparently distinct rheumatic disease syndrome associated with a specific antibody to an extractable nuclear antigen (ENA). *Am J Med* 52:148-159, 1972
2. Kay DM, Tuffanelli DL: Immunofluorescent techniques in clinical diagnosis of cutaneous disease. *Ann Intern Med* 71:753-762, 1969
3. Holborow EJ, Weir DM, Johnson CD: A serum factor in lupus erythematosus with affinity for tissue nuclei. *Br Med J* 2: 732-734, 1957
4. Mayer MM: Complement and complement fixation, *In* Kabat EA, Mayer MM (Eds): *Experimental Immunochemistry*, 2nd Ed. Springfield, IL, Charles C Thomas, 1961, p 135
5. Agnello V, Winchester RJ, Kunkel HG: Precipitin reactions of the C1q component of complement with aggregated gamma-globulin and immune complexes in gel diffusion. *Immunology* 19:909-919, 1970
6. Ginsberg B, Keiser H: A millipore filter assay for antibodies to native DNA in sera of patients with systemic lupus erythematosus. *Arthritis Rheum* 16:199-207, 1973
7. Gilliam JN, Smiley JD, Ziff M: Correlation between serum antibody to extractable nuclear antigen and immunoglobulin localization in epidermal nuclei (Abstract). *Clin Res* 22:611A, 1974
8. Gilliam JN, Prystowsky SD: Mixed connective tissue disease syndrome—Cutaneous manifestations of patients with epidermal nuclear staining and high titer serum antibody to ribonuclease-sensitive extractable nuclear antigen. *Arch Dermatol* 113:583-587, 1977
9. Prystowsky SD, Tuffanelli DL: Epidermal nuclear IgG deposition: Correlation of clinical features and laboratory findings in 47 patients, abstracted. *Clin Res* 25:100A, 1977
10. Prystowsky SD, Tuffanelli DL: Speckled (particulate) epidermal nuclear IgG deposition in normal skin: Correlation of clinical features and laboratory findings in 46 patients with a subset of connective tissue disease characterized by antibody to extractable nuclear antigen (ENA). *Arch Dermatol* 114:705-710, 1978
11. Wulff HR: *Rational Diagnosis and Treatment*, 1st Ed. Oxford, Blackwell Scientific Publications, 1976
12. Sharp GC, Irvin WS, May CM, et al: Association of antibodies to ribonucleoprotein and Sm antigens with mixed connective-tissue disease, systemic lupus erythematosus and other rheumatic diseases. *N Engl J Med* 295:1149-1154, 1976
13. Parker MD: Ribonucleoprotein antibodies: Frequency and clinical significance in systemic lupus erythematosus, scleroderma, and mixed connective tissue disease. *J Lab Clin Med* 82:769-775, 1973
14. Farber SJ, Bole GG: Antibodies to components of extractable nuclear antigen—clinical characteristics of patients. *Arch Intern Med* 136:425-431, 1976
15. Singsen BH, Bernstein BH, Kornreich HK, et al: Mixed connective tissue disease in childhood—A clinical and serologic survey. *J Pediatr* 90:893-900, 1977
16. Gilliam JN, Prystowsky SD: Conversion of discoid lupus erythematosus to mixed connective tissue disease. *J Rheumatol* 4:165-169, 1977
17. Bronshvag MM, Prystowsky SD, Traviesa DC: Vascular headaches in mixed connective tissue disease (MCTD): A report of 12 patients with mild to moderate vascular headaches associated with Raynaud's phenomenon and high titers of serum antibodies to ribonucleoprotein (RNP). *Headache* 18:154-160, 1978
18. Daniels TE, Silverman S, Michalski JP, et al: The oral component of Sjögren's syndrome. *Oral Surg* 39:875-885, 1975
19. Reichlin M, Mattioli M: Correlation of a precipitin reaction to an RNA-protein antigen and a low prevalence of nephritis in patients with systemic lupus erythematosus. *N Engl J Med* 286:908-911, 1972
20. Leibfarth JH, Persellin RH: Characteristics of patients with serum antibodies to extractable nuclear antigens. *Arthritis Rheum* 19:851-856, 1976