



---

## Uploaded to VFC Website

▶▶ **November 2012** ◀◀

---

This Document has been provided to you courtesy of Veterans-For-Change!

Feel free to pass to any veteran who might be able to use this information!

For thousands more files like this and hundreds of links to useful information, and hundreds of "Frequently Asked Questions, please go to:

[Veterans-For-Change](http://Veterans-For-Change.com)

---

*Veterans-For-Change is a 501(c)(3) Non-Profit Corporation  
Tax ID #27-3820181*

***If Veteran's don't help Veteran's, who will?***

We appreciate all donations to continue to provide information and services to Veterans and their families.

[https://www.paypal.com/cgi-bin/webscr?cmd=\\_s-xclick&hosted\\_button\\_id=WGT2M5UTB9A78](https://www.paypal.com/cgi-bin/webscr?cmd=_s-xclick&hosted_button_id=WGT2M5UTB9A78)

---

**Note:**

VFC is not liable for source information in this document, it is merely provided as a courtesy to our members.



## Advanced osteosarcoma of the maxilla: A case report

Márcio Bruno Amaral <sup>1</sup>, Ícaro Buchholz <sup>1</sup>, Belini Freire-Maia <sup>2</sup>, Peter Reher <sup>2</sup>, Paulo Eduardo Alencar de Souza <sup>3</sup>, Helenice de Andrade Marigo <sup>3</sup>, Carlos Roberto Martins <sup>3</sup>, Martinho Campolina Rebello Horta <sup>3</sup>

(1) Residents in Oral and Maxillofacial Surgery, Baleia Hospital, School of Dentistry, Pontifícia Universidade Católica de Minas Gerais, Belo Horizonte, MG, Brazil

(2) Department of Oral and Maxillofacial Surgery, Baleia Hospital, School of Dentistry, Pontifícia Universidade Católica de Minas Gerais, Belo Horizonte, MG, Brazil

(3) Oral Pathology Laboratory, School of Dentistry, Pontifícia Universidade Católica de Minas Gerais, Belo Horizonte, MG, Brazil

### Correspondence:

Prof. Martinho Campolina Rebello Horta  
Rua Ceará, 1338, 1101  
Funcionários - Belo Horizonte - MG  
Brasil - CEP 30150-311  
E-mail: martinhhorta@pucminas.br

Received: 30/10/2007

Accepted: 09/12/2007

### Indexed in:

-Index Medicus / MEDLINE / PubMed  
-EMBASE, Excerpta Medica  
-SCOPUS  
-Índice Médico Español  
-IBECs

Amaral MB, Buchholz Í, Freire-Maia B, Reher P, de Souza PEA, Marigo HA, Martins CR, Horta MCR. Advanced osteosarcoma of the maxilla: A case report. Med Oral Patol Oral Cir Bucal. 2008 Aug 1;13(8):E492-5.  
© Medicina Oral S. L. C.I.F. B 96689336 - ISSN 1698-6946  
<http://www.medicinaoral.com/medoralfree01/v13i8/medoralv13i8p492.pdf>

### Abstract

Osteosarcomas are primary malignant bone tumours in which mesenchymal cells produce osteoid. It is generally the most common malignant bone neoplasm, although lesions of the jaw are uncommon. Osteosarcoma of the jaw (JOS) presents a lower incidence of metastasis and a better prognosis than osteosarcoma of the long bones. However, patients with JOS can exhibit advanced tumours, mainly when early diagnosis is not performed. This article reports on a case of an advanced osteosarcoma of the maxilla. A 38-year-old woman was referred for evaluation and treatment of recurrent fibrous dysplasia of the facial bones. The patient related that she had been diagnosed with fibrous dysplasia four years earlier and, since the first diagnosis, she was submitted to four surgical interventions, all followed by recurrences. The main clinical findings were redness and swelling of the facial skin, upper lip ulceration, and hard palate swelling. Computed tomography showed a large hyperdense mass in right maxilla extending to right orbit and left maxillary sinus. An incisional biopsy was performed and microscopic examination showed areas of osteoid and chondroid formation surrounded by a cellular stroma. The diagnosis of osteosarcoma was established and the patient was recommended for oncologic treatment. Unfortunately, she died six months after the diagnosis due to uncontrollable local spread.

**Key words:** Osteosarcoma, bone neoplasm, maxilla.

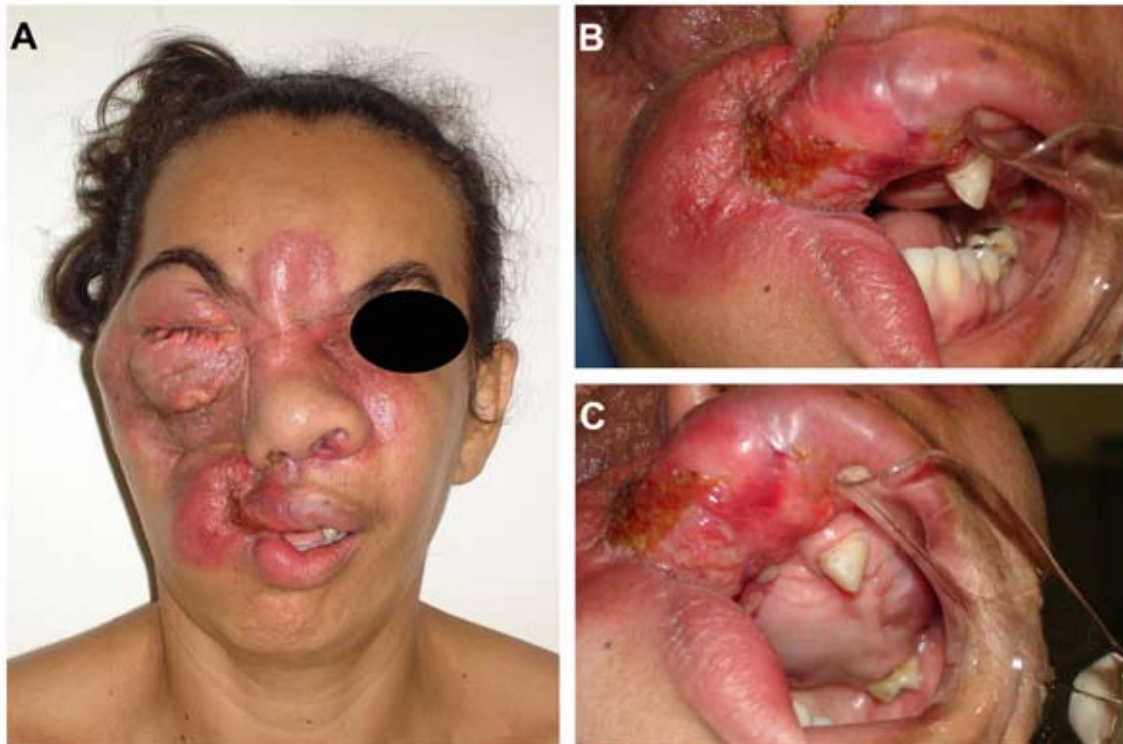
### Introduction

Osteosarcomas are primary malignant bone tumours in which mesenchymal cells produce osteoid (1-2). Although osteosarcoma is the most common malignant bone tumour, lesions of the jaw are uncommon, representing about 4% of the osteosarcomas (3). Osteosarcoma of the jaw (JOS) occurs over a wide age range, with a peak in the fourth decade of life (3-6). Although a male predilection has been reported (3,4,6), some authors have observed a slight predominance in females (5). The chief clinical features are swelling, pain, and ulceration (3-6). Radiologically, the findings may include radiolucency,

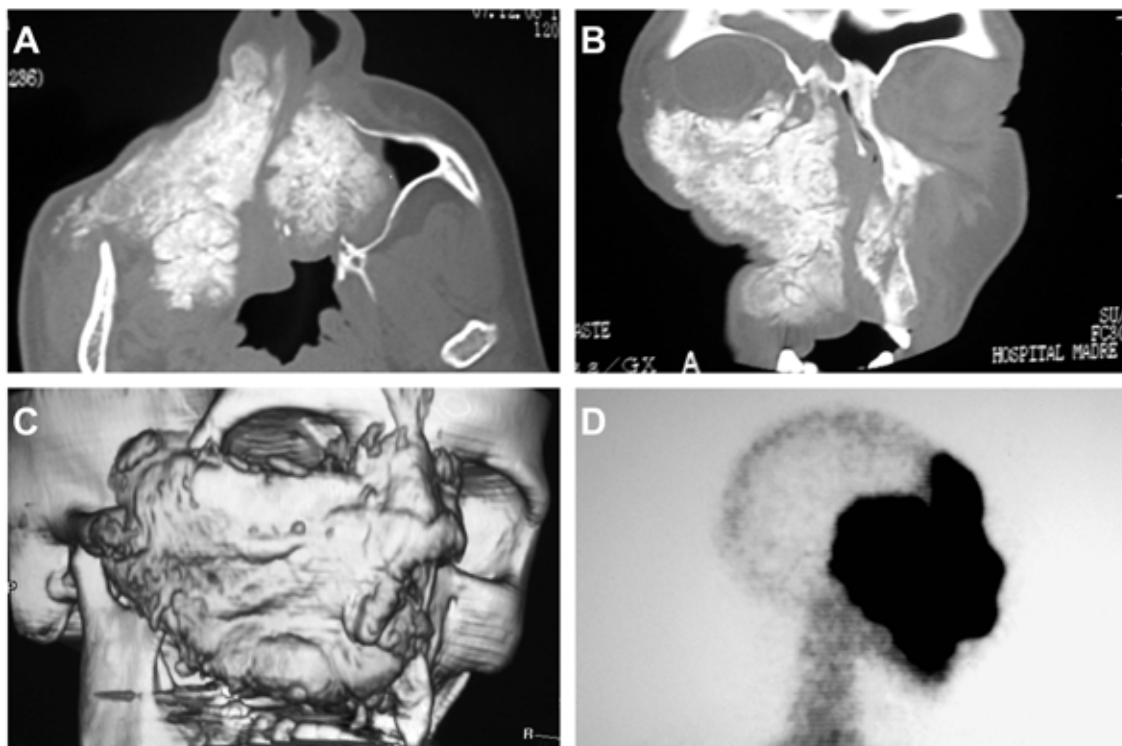
radiopacity, or a mixture of both with poorly defined irregular margins (3-6). JOS differs from osteosarcoma of the long bones in its biological behaviour, presenting a lower incidence of metastasis and a better prognosis (3,7). Early diagnosis and adequate surgical resection are the keys to high survival rates (6).

### Case Report

A 38-year-old woman was referred to the Department of Oral and Maxillofacial Surgery, Baleia Hospital, for evaluation and treatment of fibrous dysplasia of the facial bones. The patient was complaining about pain, the loss



**Fig. 1.** Clinical appearance of the lesion. (A) Redness and swelling of the skin in right perioral, right orbital, glabellar, nasal and left paranasal regions. (B and C) Upper lip ulceration and hard palate swelling covered by normal mucosa.



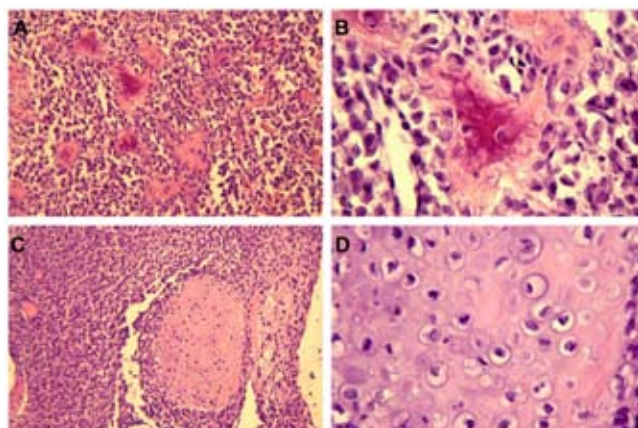
**Fig. 2.** Computed tomography and bone scintigraphy. (A and B) Computed tomography demonstrating large hyperdense mass in right maxilla extending to right orbit and left maxillary sinus. (C) Three-dimensional computed tomography reconstruction showing an expansive lesion in the right hemiface. (D) Bone scintigraphy showing a hypercaptation area in the face.

of visual acuity in the right eye and the limitation of the oral opening. According to the anamnesis, the patient had been diagnosed with fibrous dysplasia four years earlier, when she developed a hard palate painless swelling. During these four years, the patient was submitted to three osteoplasties and one partial maxillectomy, all followed by recurrences. The specimens removed in these surgical procedures had been histopathologically diagnosed as fibrous dysplasia. The patient informed that the last recurrence had begun three months prior, presenting rapid growth and skin damage.

Extraoral examination showed redness and swelling of the skin in the right perioral, right orbital, glabellar, nasal and left paranasal regions (Fig. 1A). Intraoral examination showed painful upper lip ulceration as well as hard palate swelling covered by normal mucosa (Fig. 1B and C).

Computed tomography showed a large hyperdense mass in right maxilla extending to right orbit and left maxillary sinus (Fig. 2A and B). Three-dimensional computed tomography reconstruction showed an expansive lesion in the right hemiface (Fig. 2C). Bone scintigraphy showed hypercaptation in the entire face (Fig. 2D).

An incisional biopsy was performed and the specimen was sent to the Oral Pathology Laboratory, School of Dentistry, Pontifícia Universidade Católica de Minas Gerais. Microscopic examination demonstrated areas of osteoid and chondroid formation surrounded by a cellular stroma (Fig. 3). The diagnosis of osteosarcoma was established, and the patient was recommended for oncologic treatment. Since surgical resection was not feasible, the oncology service decided to use palliative chemotherapy. The patient died six months after the osteosarcoma diagnosis due to uncontrollable local spread.



**Fig. 3.** Light microscopic observation of the tumour. Areas of osteoid formation surrounded by a cellular stroma (A and B; HE x100 in "A" and HE x400 in "B"). Area of chondroid formation surrounded by a cellular stroma (C; HE x 100). High magnification of chondroid formation with cellular atypia (D; HE x 400).

## Discussion

Although osteosarcoma is generally the most common malignant bone tumour, lesions of the jaw are rare (3). Therefore, small retrospective studies and case reports are an opportunity to report and discuss issues of clinical and diagnostic significance.

The characteristics of the case reported are in agreement with previous studies, regarding age and chief clinical features (3-6). Although the clinical alterations besides the computed tomography and bone scintigraphy findings had strongly suggested an osteosarcoma, the initial findings of the lesion were probably less suggestive. Several diseases should be included in the differential diagnosis of JOS, since its most common symptom is jaw swelling and its radiological appearance may be a radiolucent, radiopaque, or mixed area (3-6). Therefore, the differential diagnosis of JOS should include chondrosarcoma (8), Ewing's sarcoma (9), bone metastasis (10,11), fibrous dysplasia (12), osteomyelitis (12), and even lesions that do not usually affect the jaw bones as fibrosarcoma (13), leiomyosarcoma (14), or rhabdomyosarcoma (15,16).

The histopathological evaluation of the biopsy specimen showed a cellular stroma with evidence of osteoid and chondroid formation. The former is a fundamental feature for the diagnosis of osteosarcoma (1-2). Tumour classification as osteoblastic or chondroblastic was not performed, since the specimen was collected by an incisional biopsy. Moreover, no association between histological classification of JOS and survival has been reported (3).

The biological behaviour of osteosarcoma in the jaws differs from tumours of other skeletal bones. In JOS, the average onset age is 10-20 years later than long bone tumours, distant metastasis occurs less frequently, and survival rates are higher (7). Regardless of the favourable biological behaviour in relation to other skeletal bone osteosarcomas (3,7), patients with JOS may exhibit advanced tumours, mainly when early diagnosis is not performed. The present case was at first suspected to be fibrous dysplasia, and this diagnosis was sustained after the histopathological evaluation of specimens obtained in four surgical procedures. Although these procedures had been performed before the patient was referred to the Department of Oral and Maxillofacial Surgery, Baleia Hospital, it could be supposed that the first lesion presented by the patient was a low-grade central osteosarcoma, since this neoplasia is often misdiagnosed radiographically, clinically and microscopically as fibrous dysplasia (5,17-20). Furthermore, low-grade central osteosarcoma is characterized by high incidence of local recurrence after inadequate surgical removal and can transform into higher-grade osteosarcoma (17-20). Another hypothesis is the malignant transformation of fibrous dysplasia, a rare but possible event, even in absence of previous radiotherapy (21,22).

The cornerstone of primary jaw osteosarcoma treatment

is adequate surgical resection (3,7). Radiotherapy or chemotherapy can be used in association with surgical resection or alone as a palliative treatment in advanced cases (3). In the present case the oncology service decided to use palliative chemotherapy, as surgical resection was not feasible due to the advanced extension of the lesion. Unfortunately, the patient died six months after the osteosarcoma diagnosis due to uncontrollable local spread, the most common cause of death in JOS (3).

In conclusion, although JOS presents a better prognosis than osteosarcoma of the long bones, patients with JOS can exhibit advanced tumours, mainly when early diagnosis is not performed. Clinicians and pathologists should be aware of its characteristics and main differential diagnosis to avoid late recognition, as demonstrated in the case reported.

## References

1. Fechner RR, Mills SE. Atlas of tumor pathology: Tumors of the bones and joints. Washington: Armed Forces Institute of Pathology; 1993.
2. Fletcher CDM, Unni KK, Mertens F. Pathology and genetics of tumors of the soft tissue and bone. World Health Organization Classification of Tumours. Lyon: Iarc Press; 2002.
3. August M, Magennis P, Dewitt D. Osteogenic sarcoma of the jaws: factors influencing prognosis. *Int J Oral Maxillofac Surg.* 1997 Jun;26(3):198-204.
4. Doval DC, Kumar RV, Kannan V, Sabitha KS, Misra S, Vijay Kumar M, et al. Osteosarcoma of the jaw bones. *Br J Oral Maxillofac Surg.* 1997 Oct;35(5):357-62.
5. Bennett JH, Thomas G, Evans AW, Speight PM. Osteosarcoma of the jaws: a 30-year retrospective review. *Oral Surg Oral Med Oral Pathol Oral Radiol Endod.* 2000 Sep;90(3):323-32.
6. Mardinger O, Givol N, Talmi YP, Taicher S. Osteosarcoma of the jaw. The Chaim Sheba Medical Center experience. *Oral Surg Oral Med Oral Pathol Oral Radiol Endod.* 2001 Apr;91(4):445-51.
7. Chindia ML. Osteosarcoma of the jaw bones. *Oral Oncol.* 2001 Oct;37(7):545-7.
8. Saini R, Abd Razak NH, Ab Rahman S, Samsudin AR. Chondrosarcoma of the mandible: a case report. *J Can Dent Assoc.* 2007 Mar;73(2):175-8.
9. Gorospe L, Fernández-Gil MA, García-Raya P, Royo A, López-Barea F, García-Miguel P. Ewing's sarcoma of the mandible: radiologic features with emphasis on magnetic resonance appearance. *Oral Surg Oral Med Oral Pathol Oral Radiol Endod.* 2001 Jun;91(6):728-34.
10. Raubenheimer EJ, Noffke CE. Pathogenesis of bone metastasis: a review. *J Oral Pathol Med.* 2006 Mar;35(3):129-35.
11. Otmani N, Khattab M. Metastatic neuroblastoma to the mandible in a 3-year-old boy: a case report. *Med Oral Patol Oral Cir Bucal.* 2007 May 1;12(3):E201-4.
12. Petrikowski CG, Pharoah MJ, Lee L, Grace MG. Radiographic differentiation of osteogenic sarcoma, osteomyelitis, and fibrous dysplasia of the jaws. *Oral Surg Oral Med Oral Pathol Oral Radiol Endod.* 1995 Dec;80(6):744-50.
13. Soares AB, Lins LH, Macedo AP, Pereira-Neto JS, Vargas PA. Fibrosarcoma originating in the mandible. *Med Oral Patol Oral Cir Bucal.* 2006 May 1;11(3):E243-6.
14. Pinheiro Jde J, Alves Sde M Jr, Okuda E, Jorge WA, Jaeger RG, De Araújo NS. Primary leiomyosarcoma of the mandible. A case report. *Med Oral Patol Oral Cir Bucal.* 2007 Jan 1;12(1):E56-9.
15. França CM, Caran EM, Alves MT, Barreto AD, Lopes NN. Rhabdomyosarcoma of the oral tissues--two new cases and literature review. *Med Oral Patol Oral Cir Bucal.* 2006 Mar 1;11(2):E136-40.
16. Loducca SV, Mantesso A, De Oliveira EM, De Araújo VC. Intraosseous rhabdomyosarcoma of the mandible: a case report. *Int J Surg Pathol.* 2003 Jan;11(1):57-60.
17. Raubenheimer EJ, Noffke CE. Low-grade intraosseous osteosarcoma of the jaws. *Oral Surg Oral Med Oral Pathol Oral Radiol Endod.* 1998 Jul;86(1):82-5.
18. Yamashiro M, Komori A. Osteosarcoma mimicking fibrous dysplasia of the jaw. *Int J Oral Maxillofac Surg.* 1987 Feb;16(1):112-5.
19. Franceschina MJ, Hankin RC, Irwin RB. Low-grade central osteosarcoma resembling fibrous dysplasia. A report of two cases. *Am J Orthop.* 1997 Jun;26(6):432-40.
20. Muramatsu K, Hashimoto T, Seto S, Gondo T, Ihara K, Taguchi T. Low-grade central osteosarcoma mimicking fibrous dysplasia: a report of two cases. *Arch Orthop Trauma Surg.* 2008 Jan;128(1):11-5.
21. Ruggieri P, Sim FH, Bond JR, Unni KK. Malignancies in fibrous dysplasia. *Cancer.* 1994 Mar 1;73(5):1411-24.
22. Hoshi M, Matsumoto S, Manabe J, Tanizawa T, Shigemitsu T, Izawa N, et al. Malignant change secondary to fibrous dysplasia. *Int J Clin Oncol.* 2006 Jun;11(3):229-35.